

## A Radiological Study on Morphometry and Variations of the Renal Vein Using CT Imaging

Vignesh. M, Nirmala. D, Sudhakar. P, Preethi. R, Kavitha. S\*

\*Tutor, Dept. of Anatomy, Meenakshi Medical College, Kanchipuram, Tamil Nadu, India.  
Associate Professor, Dept. of Anatomy, Meenakshi Medical College, Kanchipuram, Tamil Nadu, India.  
Professor, Dept. of Anatomy, Meenakshi Medical College, Kanchipuram, Tamil Nadu, India.  
Assistant Professor, Dept. of Anatomy, Meenakshi Medical College, Kanchipuram, Tamil Nadu, India.  
Tutor, Dept. of Anatomy, Meenakshi Medical College, Kanchipuram, Tamil Nadu, India.

### Abstract

**Purpose:** Venous anatomy of the kidney is considered important and subjected to many variations. The commonest venous variation is presence of multiple renal veins and retroaortic left renal vein. In this study we evaluated the morphometry of renal vein and its variations.

**Methods:** Prospective study was conducted on 100 kidney donors who underwent CT angiograms. Renal angiographic images were analysed for length, width of renal vein and its variations. The length was measured from hilum upto its termination and width measured near hilum of kidney and near termination.

**Results:** The mean length of right renal vein was 3.01cm and left renal vein was 7.01cm. The mean width of right renal vein near termination was 1.10cm and near hilum was 1.03cm. The mean width of left renal vein near termination was 0.88cm and near hilum was 0.99cm. out of 100 kidney donors the variation of renal vein was found on 23 individual. In this 19 had accessory renal vein and 4 individual had retroaortic left renal vein.

**Conclusion:** Analysing CT Images demonstrated the morphometry of renal vein and its variations. Presence of these variations can be susceptible to trauma and threat to abdominal surgical procedure especially during kidney transplantation and retroperitoneal surgery.

### Keyword:

RENAL VEIN, CT

### Introduction

The venous blood of kidney is drained by renal veins, which include right renal vein and left renal vein. Each renal vein originates from the confluence of a variable number of primary tributaries that emerge from the kidney, and drains into the inferior vena cava. Since the inferior vena cava is on the right side, the right renal vein is relatively short and it doesn't receive any tributary<sup>1</sup>. The left renal vein is longer than right renal vein and receives the left inferior phrenic vein, left suprarenal vein, left gonadal vein (left testicular vein in males, left ovarian vein in females) and left 2<sup>nd</sup> lumbar vein. This is in contrast to the right side, where these veins drain directly into the inferior vena cava<sup>2,3</sup>. The vascular pattern of the kidney has been a topic of debate and repeated anatomical investigations, because there is no similarity in the literature regarding its detailed morphometry. During the living donor nephrectomy, the left kidney is used more often as a donor organ because its vein is longer than the right renal vein. The left renal vein crosses the abdominal aorta anteriorly before draining into inferior vena cava<sup>4</sup>. Usually there are single renal vein on both sides, also as a variant expression like additional renal veins draining separately into the inferior vena cava has also been reported<sup>5</sup>. The frequency of an additional renal vein is considerably higher at the right side (7–38%) in comparison with the left side (1–3%)<sup>6,7</sup>. The other kind of rare renal vein variations like circumaortic course, renal collar and retro aortic course can be explained due to the complexity in the embryological development of the left renal vein<sup>8,9,10</sup>. The morphometric study and its frequency of variations in the renal veins may be useful for diagnostic imaging, surgical procedures (retroperitoneal approaches), urological procedures, and renal transplantation<sup>11,12</sup>. Since there are detailed studies done on morphometric analysis and variations of renal veins, this study was done to measure length, diameter and frequency of variations in renal veins.

## Materials and methods

This prospective study was conducted on 100 kidney donors of age group between 25-60 years after obtaining Human ethical clearance (IHEC:MSc26/SU139/2011). The CT angiographic images of those individuals willing to donate kidney were collected from specialized scan centre in Chennai during the period of November 2014 to June 2015. Individuals with any history of abdominal trauma and surgery, elevated creatinine levels and hypertension were excluded from this study. Renal angiographic images were collected and analyzed for the length, width and variations in course and number. The length of renal veins was measured from the hilum upto its termination in inferior vena cava. The width was measured near the termination and near the hilum of kidney. The data obtained was entered in MS excel sheet and analyzed using SPSS software for calculating mean and standard deviation. Also the renal veins were analysed for any variations like accessory vein and retro aortic course.

## Results

The CT images obtained were measured for length and width of renal veins (fig: 1).

### Morphometric analysis of renal veins:

The mean length of right renal vein was 3.01cm and left renal vein was 7.01cm (Table 1). The length of right renal vein varied from 1.2 to 5.2cm and left renal vein length varied from 3.5 to 10.1 cm (fig 2). The length of right renal vein in 45% of individuals varied from 2.1cm to 3.0cm and 37% of individuals varied from 3.1cm to 4cm (Fig.5) (Table:2). The length of left renal vein in 35% of individuals varied from 7.1 to 8.0cm and 34% of individuals varied from 6.1 to 7.0 cm(Fig:6) (Table:3). The mean width of right renal vein near termination was 1.10cm and near hilum was 1.03cm. Similarly the mean width of left renal vein near termination was 0.88cm and near hilum was 0.99cm (Table 4).

### Variations in the renal vein:

Out of 100 kidney donors the variations in renal vein was found in 23 individuals (Table 5) (Fig: 7) in which 19 individuals had right accessory renal vein (fig.3) and 4 individuals had retroaortic left renal vein (fig.4) (Table 6).

**Table 1: Mean Length Of Renal Vein**

S.No	Renal vein length	Mean ± SD (cm)
1.	Right Renal vein length	3.01 ± 0.95
2.	Left Renal vein length	7.01 ± 1.14

**Table 2: Length Of Right Renal Vein**

S.No	Range cm	Number of Individuals
1	1.2 – 2.0	11
2	2.1 – 3.0	45
3	3.1 – 4.0	37
4	4.1 – 5.2	7

**Table 3: Length Of Left Renal Vein**

S.No	Range cm	Number of Individuals
1	3.5 – 4.0	2
2	4.1 – 5.0	3
3	5.1 – 6.0	10
4	6.1 – 7.0	34
5	7.1 – 8.0	35
6	8.1 – 9.0	14
7	9.1 – 10.1	2

# PULMONOLOGY

**Table 4: Mean Width Of Renal Vein**

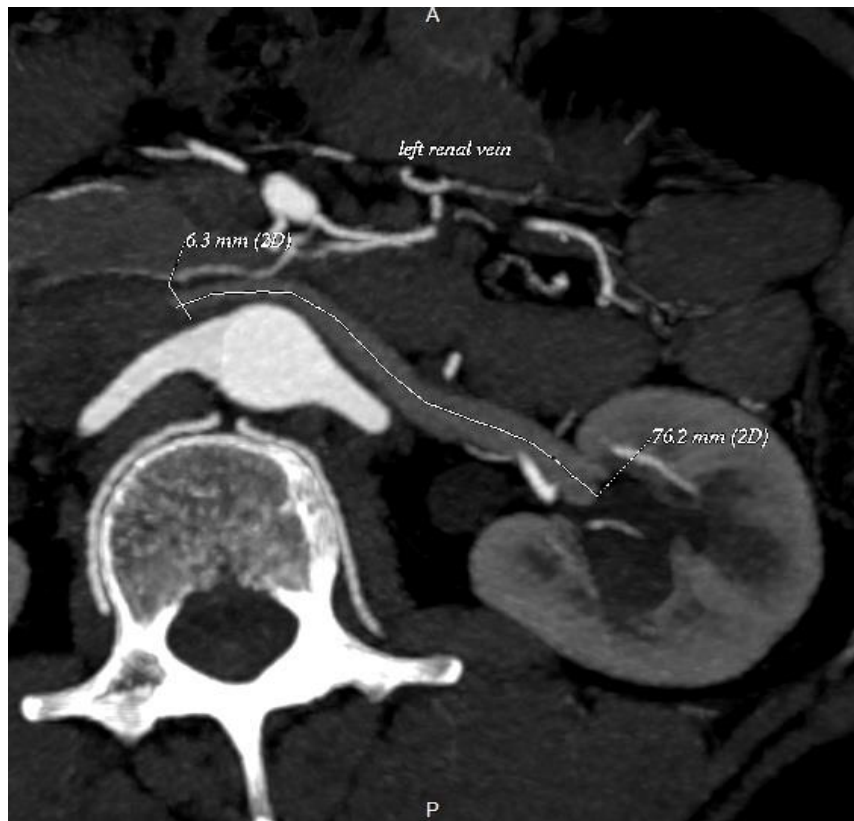S.No	Renal vein width	Mean $\pm$ SD(cm)
1.	Right Renal vein width near termination	1.10 $\pm$ 0.27
2.	Left Renal vein width near termination	0.99 $\pm$ 0.74
3.	Right Renal vein width near hilum	1.03 $\pm$ 0.27
4.	Left Renal vein width near hilum	0.88 $\pm$ 0.22

**Table 5: Number Of Variations In Renal Vein**

S.No	Normal & variations of renal vein	Number of individuals
1.	Normal	77
2.	Variations	23

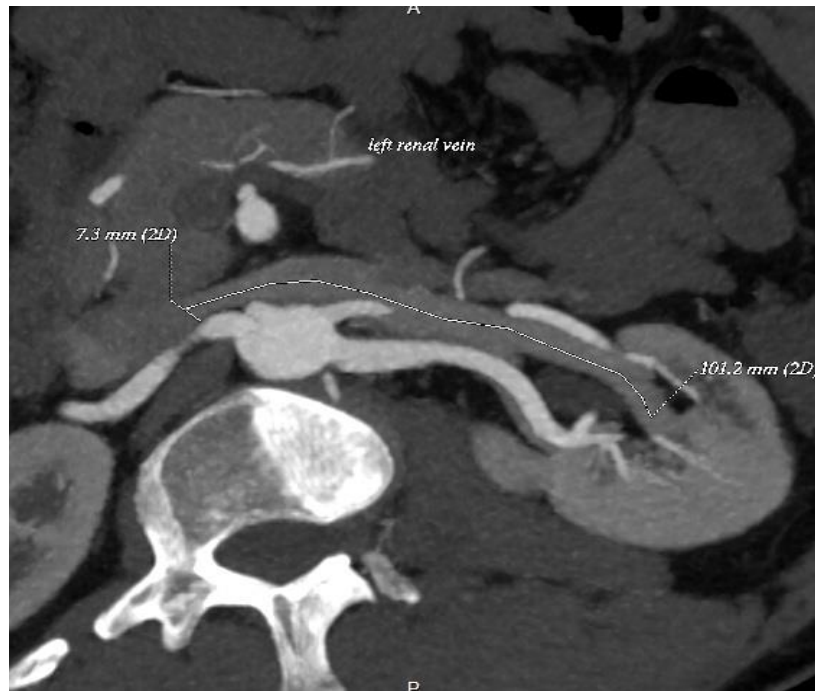**Table 6: Variations In Renal Vein**

S.No	Variations of renal vein	Number of individuals
1.	Accessory renal vein	19 (all on right side)
2.	Retro aortic left renal vein	4 (all on left side)

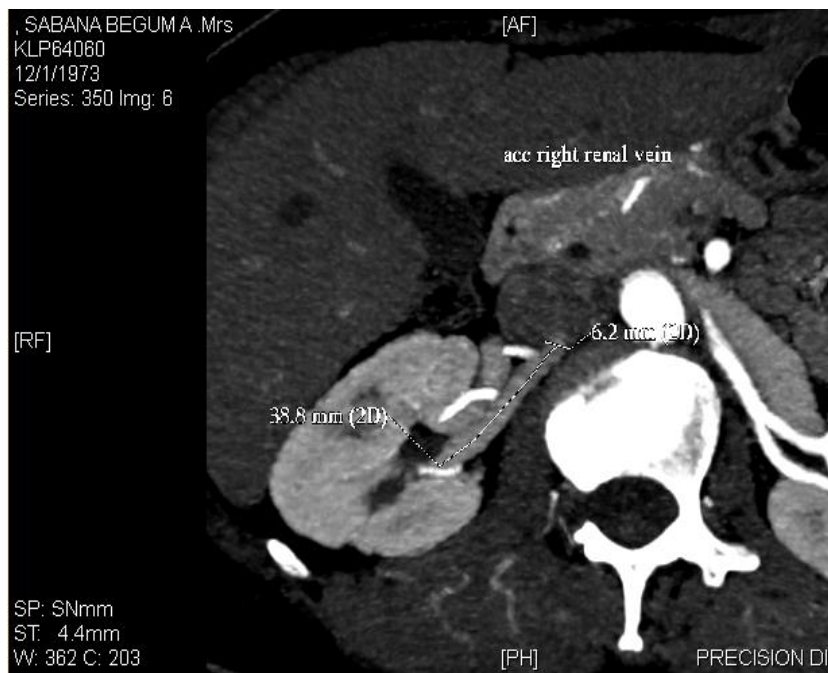


**Figure .1: CT image showing measurement of renal vein.**

# PULMONOLOGY



**Fig.2: CT image showing long left renal vein**



**Fig.3: CT image showing right accessory renal vein**

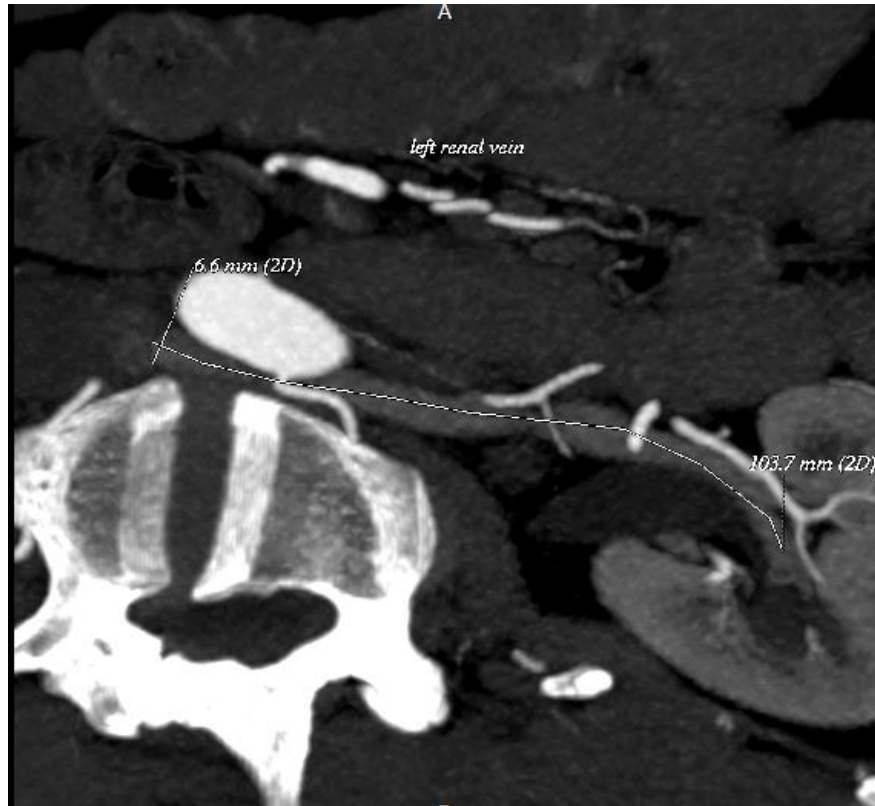

Fig.4: CT image showing retroaortic long left renal vein

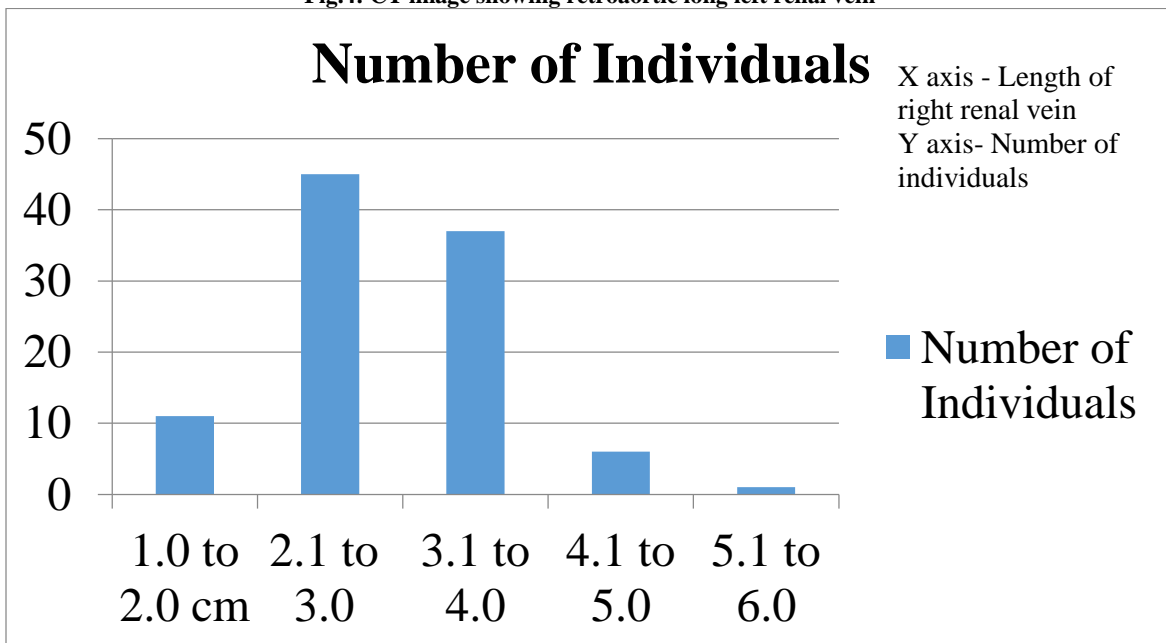


Figure 5: showing number of individuals in each range in length of the right renal vein

# PULMONOLOGY

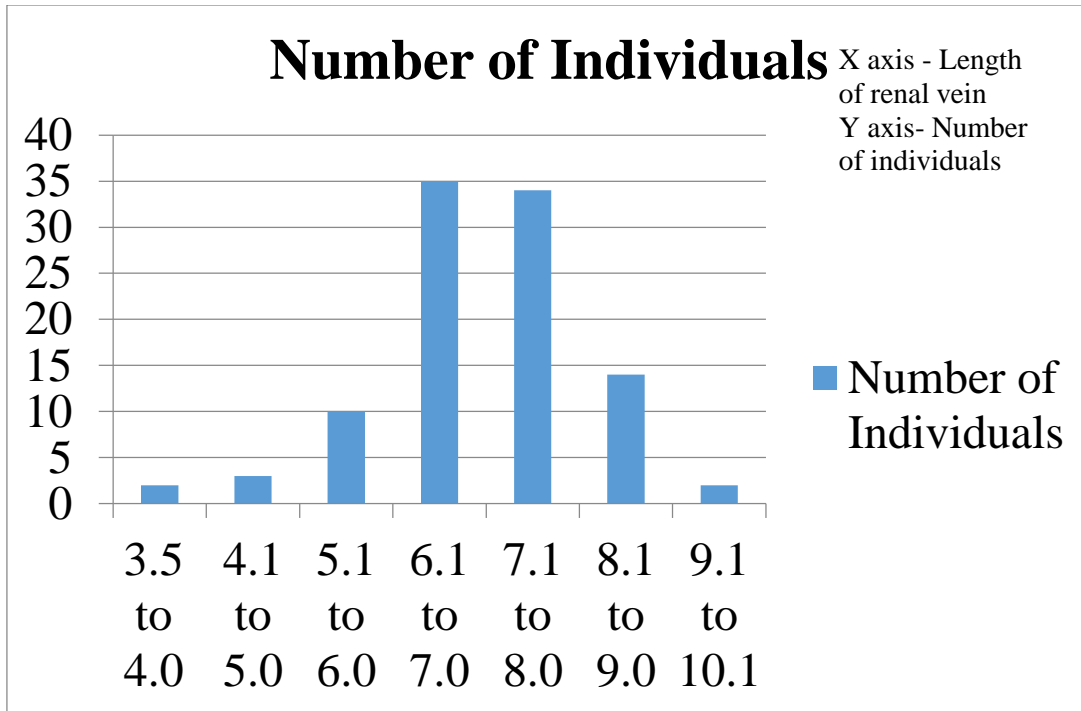


Figure 6: showing number of individuals in each range in length of the left renal vein

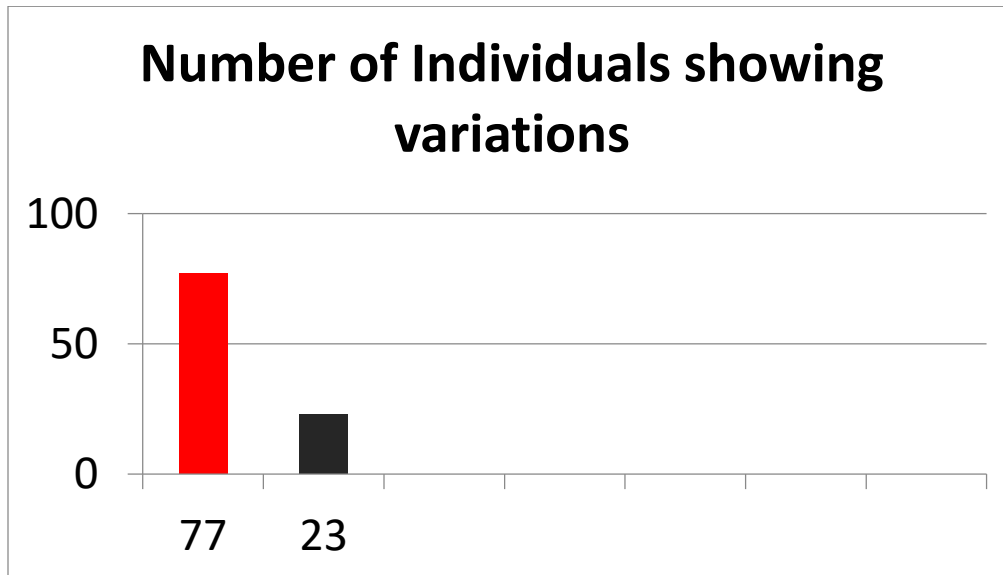


Figure 7: showing number individuals showing normal pattern and variations in renal veins:

## Discussion

### Morphometric analysis of renal vein:

In this study the mean length of right renal vein was  $3.01 \pm 0.95$  cm and mean length of left renal vein was  $7.01 \pm 1.14$  cm. One of the previous study showed that the mean right renal vein length was  $2.36 \pm 0.821$  cm, mean left renal vein length was  $5.65 \pm 1.27$  cm and the right renal vein range from 2.4-2.6 cm, left renal vein range from 5.4-5.9 cm [13]. Another study on right renal vein showed that the length varied from 21 to 71 mm which was similar to the

current study [14]. The studies on left renal vein also showed similar results that the length varied from 2.6cm to 8.0 cm [15, 16].

The mean width of right renal vein near the entry into inferior vena cava was  $1.10 \pm 0.27$ cm which was similar to previous study which showed the variation from  $1.09 \pm 0.156$  cm [13] but slightly smaller than reported by Sathyapal 2003 [17] and, Janschek et al. (2004) [18] where they reported 1.2 cm. The mean width of left renal vein was  $0.99 \pm 0.74$  which was slightly smaller as compared to other studies where they reported 1.23 cm [13] [6]. The differences in length and width of renal veins in the literature reported can be explained by the size of the subjects analysed and the diversity in the population with their respective phenotypic expressions.

### Variations in renal veins:

This study showed 23% of individuals had renal vein variations out of which 19 were accessory renal veins and 4 were retro aortic left renal vein. The occurrence of accessory right renal vein was a common variation (19%) which was less compared to other studies like Sathyapal 1999 [5] and Okada et al 2010 [19] where they showed 31% and 33% respectively. The prevalence of right and left accessory renal veins done by various studies were tabulated (table:7)

Authors	Right accessory renal vein	Left accessory renal vein
Sathyapal 1999	31%	2.6%
Bregman 2000 [20]	18%	9%
Dhar P 2004 [21]	12%	3%
Anupma 2011 [22]	33%	3.3%
Okada 2010	33%	-
Current study	19%	-

**Table 7: Prevalence of accessory renal vein**

### Clinical implications

The multiple renal veins can be susceptible to trauma and threat to abdominal surgical procedure especially during kidney transplantation and retroperitoneal region. Also the use of kidney with accessory renal vessels has been discouraged due to increased risk to donor because of multiple vessels anastomosis, prolonged ischemia time and poorly controlled hypertension from segmental infarcts of allograft (24). Direct venous extension of renal cell carcinoma via the renal vein is of normal occurrence and the presence of extra renal veins might prove an extra route for spread of metastasis. This can enhance the spread of primary renal cell carcinoma to multiple sites in the body.

### Retro aortic left renal vein:

In this study 4% of individuals had retro aortic left renal veins when compared to other studies in which it ranged from 0.5% to 6.6%. This retro aortic renal vein can be compressed between aorta and lumbar spine leading to posterior nutcracker phenomenon manifesting as abdominal pain with or without hematuria. Also this compression can reflux venous blood to gonadal veins resulting in varicocele and varicose veins in lower limb. This retroaortic left renal vein can be associated with pelvic congestion syndrome in females. The retroaortic vein can be obstructed by peritoneal growths leading to nephritis if it is prolonged [25]. The prevalence of retroaortic left renal vein were tabulated in table 8.

**Table 8: prevalence of retroaortic left renal vein**

Author	Retroaortic left renal vein
Sathyapal et al 1999 [5]	0.5%
Holden et al 2005 [23]	3%
Anupma et al 2011 [22].	6.6%
Current study	4%

### Embryological basis of accessory renal vein:

The cardinal veins form the main venous drainage system of the embryo. During fourth week this system consists of anterior and posterior cardinal veins joining together to form common cardinal veins. Around 7-8 weeks bilateral symmetrical venous system converts into unilateral right side inferior vena cava. Two or more renal veins are present on each side of inferior vena cava draining kidney, one on anterior side and other on posterior side. On the right side these anterior and posterior veins fuse together and form single renal vein, persistence of which can lead to

accessory renal vein. Due to the right shift of venous system the retention of accessory veins on left side is very rare, So the accessory right renal veins are common [22]

## References

1. Cooley DA, Wukasch DC, eds. Techniques in vascular surgery. Philadelphia: Saunders, 1978:282.
2. Anson BJ, Cauldwell EW, Pick JW, Beaton LE. The anatomy of the pararenal system of veins, with comments on the renal arteries. *J Urol* 1948;60:714-37.
3. Baptista-Silva JCC, Cal RGR, Castro MJ, Veríssimo MJM, Câmara ALG. Estudo anatômico das veias renais e suas variações, observação durante as nefrectomias em doadores vivos. *Rev Col Bras Cir* 1995;22(2): 18.
4. Anson BJ, Daseler EH. Common variations in the renal blood supply. *Surg Gynecol Obstet* 1961;112:439-49.
5. Satyapal KS, Kalideen JM, Haffjee AA, Sing B, Robbs JV, Left renal vein variations, *Surg Radiol Anat*, 1999, 21(1):77- 81.
6. Satyapal KS, Rambiritch V, Pillai G, Additional renal veins: incidence and morphometry, *Clin Anat*, 1995, 8(1):51-55.
7. Duques P, Rodrigues JR, Da Silva Neto FB, Neto EMVS, De Tolêdo ES, Estudo anatômico da veia renal esquerda de cadáveres humanos brasileiros (Anatomical study of the left vein of human Brazilians cadavers), *Medicina (Ribeirão Preto)*, 2002, 35(2):184-191.
8. Thomas VT, Surgical implications of retroaortic left renal vein, *Arch Surg*, 1970, 100(6):738-741.
9. Mathews R, Smith PA, Fishman EK, Marshall FF, Anomalies of the inferior vena cava and renal veins: embryologic and surgical considerations, *Urology*, 1999, 53(5):873-880.
10. Kramer B, The incidence of the renal venous collar in South African blacks, *S Afr Med J*, 1980, 57(21):875-876.
11. Hoeltl W, Hruby W, Aharinejad S, Renal vein anatomy and its implications for retroperitoneal surgery, *J Urol*, 1990, 143(6): 1108-1114.
12. Nam JK, Park SW, Lee SD, Chung MK, The clinical significance of a retroaortic left renal vein, *Korean J Urol*, 2010, 51(4): 276-280.
13. Luis ernesto Ballesteros, Vladimir Saldarriaga, Luis Miguel Ramirez. Morphologic evaluation of the renal veins: a study with autopsy material from Colombian subjects *Rev J Morphol Embryol* 2014, 55(1):77-81
14. Janschek EC1, Rothe AU, Hölzenbein TJ, Langer F, Brugger PC, Pokorny H, Domenig CM, Rasoul-Rockenschaub S, Mühlbacher F. Anatomic basis of right renal vein extension for cadaveric kidney transplantation. *Urology*. 2004 Apr;63(4):660-4
15. Duques P, Rodrigues JR, Da Silva Neto FB, Neto EMVS, De Tolêdo ES, Estudo anatômico da veia renal esquerda de cadáveres humanos brasileiros (Anatomical study of the left vein of human Brazilians cadavers), *Medicina (Ribeirão Preto)*, 2002, 35(2):184-191.
16. Gillot C, La veine rénale gauche. Etude anatomique, aspects angiographiques, abord chirurgical (The left renal vein. Anatomical study, angiographic aspects and surgical approach), *Anatomia Clinica*, 1978, 1(2):135-156.
17. Satyapal KS, The renal veins: a review, *Eur J Anat Suppl*, 2003, 7(Suppl 1):43-52.
18. Beckmann CF, Abrams HL, Renal venography: anatomy, technique, applications, analysis of 132 venograms, and a review of the literature, *Cardiovasc Intervent Radiol*, 1980, 3(1):45-70.
19. Y. Okada, Y. Kayashima, N. Nishi, W. Mizukoshi, T. Watadani, Y. Matsuo, E. Kozawa, F. Kimura; Hidaka, Saitama/JP. Anatomic variation of the right renal vein: MDCT evaluation with interactive 3D reformation. 10.1594/ecr2010/C-1305
20. Bregman RA, Afifi AK and Miyauchi R. Virtual Hospital: Illustrated encyclopedia of human renal arteries: 2000; 15-8.
21. Dhar P. and Ajmani ML. Major anomalies of left renal vein and inferior vena cava. *Int Med J*. 2004; (2): Dec.
22. Anupma gupta, Raman gupta, Rikki singal . Congenital Variations of Renal Veins: Embryological Background And Clinical Implications. *Journal of Clinical and Diagnostic Research*. 2011 November (Suppl-1), Vol-5(6): 1140-1143.
23. Holden A, Smith A, Dukes P, Pilmore H, Yasutomi M. Assessment of 100 live potential renal donors for laparoscopic nephrectomy with multi-detector row helical CT. *Radiology* 2005;237:973-980
24. Mandal AK, Cohen C, Montgomery RA, Kavoussi LR, Ratner LE. Transplantation 660-4. 2001. p. 1
25. Singla RK, Sharma T, Gupta R. Retro-aortic left renal vein with left suprarenal vein draining into inferior vena cava. *IJAV*. 2010; (3):134-7.